
Batch Name: 94267

Batch Creator: SWORD 1

Batch Creation Date: 7/26/2006

Batch Creation Time: 12:59:49

Number of Pages: 9 [All]

Printed by: SWORD 1

Print Date: 7/26/2006

Print Time: 13:2:3

From fill@www.libraries.wright.edu Wed Jul 26 10:48:45 2006
Return-Path: <fill@www.libraries.wright.edu>
Received: from mulnx12.mcs.muohio.edu (mulnx12.mcs.muohio.edu [134.53.6.67])
by sigerson.sword.org (8.13.4/8.13.4/Debian-3) with ESMTTP id k6QEmjbu009310
for <requests@sword.org>; Wed, 26 Jul 2006 10:48:45 -0400
Received: from mulnx24.mcs.muohio.edu (mulnx24.mcs.muohio.edu [134.53.6.11])
by mulnx12.mcs.muohio.edu (Switch-3.1.8/Switch-3.1.7) with ESMTTP id k6QE161a009866
for <requests@sword.org>; Wed, 26 Jul 2006 10:47:06 -0400
Received: from sms1.wright.edu (sms1.wright.edu [130.108.66.31])
by mulnx24.mcs.muohio.edu (Switch-3.1.8/Switch-3.1.7) with SMTP id k6QE1597032177
for <requests@sword.org>; Wed, 26 Jul 2006 10:47:05 -0400
Received: from conversion-daemon.sms1.wright.edu by sms1.wright.edu
(iPlanet Messaging Server 5.2 HotFix 2.09 (built Nov 18 2005))
id <OJ3000601LWPFPP@sms1.wright.edu>
(original mail from fill@www.libraries.wright.edu)
for requests@sword.org; Wed, 26 Jul 2006 10:39:39 -0400 (EDT)
Received: from staff150 ([130.108.169.150])
by sms1.wright.edu (iPlanet Messaging Server 5.2 HotFix 2.09 (built Nov 18
2005)) with ESMTTP id <OJ3000KDHMY9H@sms1.wright.edu> for requests@sword.org;
Wed, 26 Jul 2006 10:39:35 -0400 (EDT)
Date: Wed, 26 Jul 2006 14:39:34 +0000 (GMT)
From: Fordham Interlibrary Loan <fill@www.libraries.wright.edu>
Subject: Please fill request
To: requests@sword.org
Message-id: <250010761.729972612285148121@www.libraries.wright.edu>
Content-transfer-encoding: 7BIT
X-Real-ConnectIP: 130.108.66.31
X-Scanned-By: MIMEDefang 2.45
X-Scanned-By: MIMEDefang 2.52 on 134.53.6.11

This request has been forwarded from ILL by barb.

Please fill this request for FORDHAM HEALTH SCIENCES LIBRARY

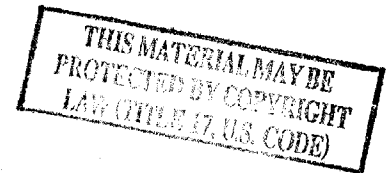94267

Call Number: 81259050104

Journal Title: American Journal of Obstetrics and Gynecology
Journal Vol: 57
Journal Issue:
Journal Year: 1949
Article Title: Indications for hormone pellets in therapy of endocrine and gynecologic disorder
Article Author: Greenblatt
Article Pages: 294-301

Customer Information:

Name: Glaser, Rebecca
Status: Faculty
Address: SOUTHVIEW (via Kettering Hosp),
Site:
E-Mail Address: rglaser@woh.rr.com
Phone: 937-885-4555
Department: School of Medicine



8pp

scanned

7/20/06

INDICATIONS FOR HORMONAL PELLETS IN THE THERAPY OF ENDOCRINE AND GYNECIC DISORDERS*

ROBERT B. GREENBLATT, M.D., AND ROLAND R. SURAN, M.D., AUGUSTA, GA.

(From the Department of Endocrinology, University of Georgia School of Medicine)

IT HAD been noted by many investigators in both animal and clinical experimentation that implantation of hard compressed pellets of crystalline steroids resulted in a slow and more physiologic absorption of the hormone than that observed after parenteral administration. Since the amount of the hormone released to the organism is continuous though minute in quantity, it is conceivable that by this method the endogenous mechanism of hormonal secretion is more nearly approached and the physiologic action of the hormone more closely imitated.¹⁻⁶ In 1942 Corner⁷ predicted that, "pellets will probably be used in human cases in which long continued action is required, not only because of the continuous absorption, but also because insertion of the pellet, which can be done through a hollow needle, avoids repeated hypodermic punctures."

The numerous objections to the repeated parenteral administration of hormonal preparations are apparent to both physician and patient. The implantation of hormonal pellets may be undertaken in a great variety of conditions requiring prolonged hormonal therapy. Besides eliminating the necessity and inconvenience of frequent injections, the economy of this mode of therapy places it within reach of most patients. Satisfactory results may be obtained for periods up to six months and longer.

Technique of Pellet Injection

With the use of the Kearns Pellet Injector (Fig. 1), the disadvantages of previous methods of subcutaneous and subfascial pellet implantation have been largely eliminated. Implantation by these earlier methods was followed by expulsion of the pellet in as many as 15 per cent of cases, whereas, with the Kearns instrument pellet extrusion is rarely seen, and in our experience, occurred in less than 2 per cent. In those instances in which the pellets were recovered after varied periods, and weighed, it was found that absorption closely followed the more or less constant curves previously reported.^{8, 9}

An area of skin is chosen on the anterior abdominal wall about one inch medial to the anterior superior spine of the iliac crest, on either the right or left side. The skin is cleansed with any of the accepted antiseptic preparations, and then anesthetized with 1 or 2 c.c. of a 2 per cent solution of procaine hydrochloride (Fig. 2). The sterilized pellet injector with stylet in place is directed parallel to the inguinal ligament, and inserted subcutaneously to the depth of the first bolt (Fig. 3). The stylet is removed, and the pellet placed in the groove at the exposed end of the hollow needle. Care should be taken when placing

*This work was aided by a grant from Schering Corporation, Bloomfield, N. J. Supplies of pellets of estradiol, testosterone (Oreton-F), progesterone, and desoxycorticosterone acetate (Cortate) were made available through the courtesy of Dr. W. H. Stoner and Dr. Edward Henderson of Schering Corporation.

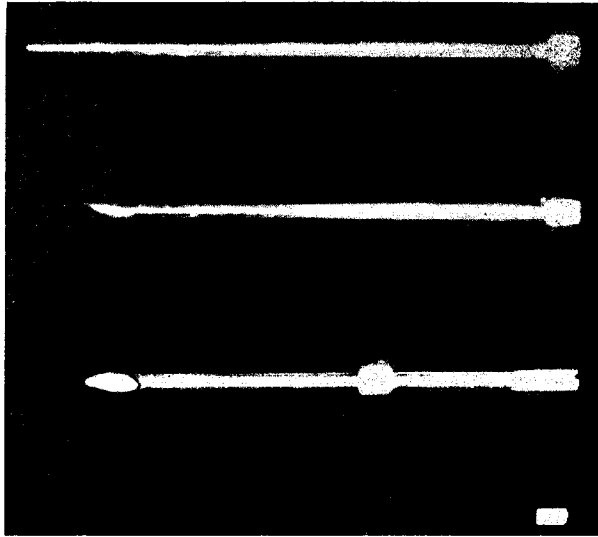


Fig. 1.—The Kearns Pellet Injector (unassembled) with pellet.

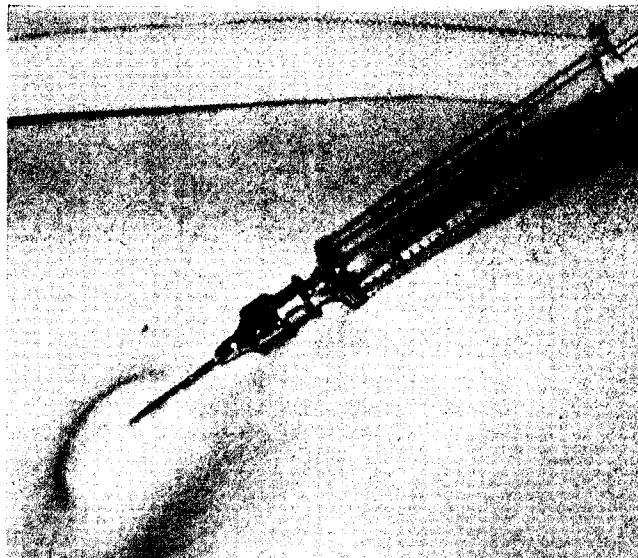


Fig. 2.—Anesthetizing the skin with procaine hydrochloride solution.

i-
ls
it
e
r-
n
e
e
se
h
”
of
a-
i-
y
y
ed

of
en
oy
re
e-
re
ly
ch
ft
is,
o-
ed
of
ve
ig
es
te
rd

the pellet into the cannula, as the pellet cannot be re-sterilized if it falls out and becomes contaminated. By holding the sterile tray beneath the groove, the pellet will be caught in this tray, and can be replaced (Fig. 4). As many pellets as indicated may be added. Twelve pellets have been implanted by a single injection. The blunt plunger is then fully inserted, gently pushing the pellets into the subcutaneous tissues. The instrument is withdrawn, and a dry dressing placed over the wound. The pellets may be palpated in the subcutaneous tissues of the anterior abdominal wall, just above the middle of Poupart's ligament.

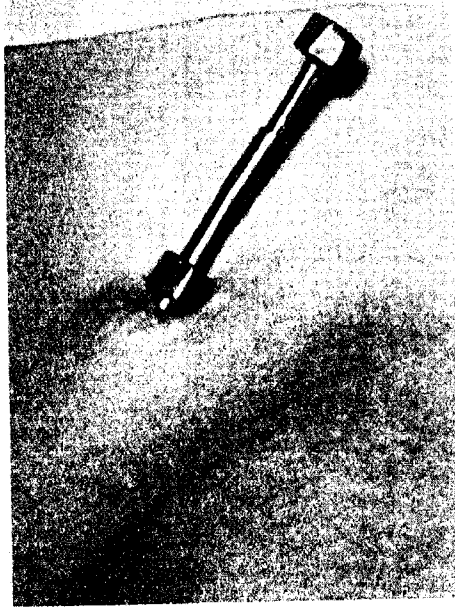


Fig. 3.




Fig. 4.

Fig. 3.—Subcutaneous insertion of the cannula with stylet.

Fig. 4.—Introduction of the pellets into the groove at the exposed end of the cannula.

Absorption

If pellets are manufactured under standard conditions, i.e., uniformly compressed crystalline material, it holds that pellets of greater weight will be of proportionately greater size. The rate of absorption, per pellet, will depend on its surface area. The percentage of absorption of each weight group of pellets will follow its own definite curve. The total rate of absorption on any given day or any given time depends on the number of pellets implanted and not on the actual weight of the pellets. Since pellets of similar size are more or less absorbed at moderately uniform rates, and since the rate of absorption depends on the number of pellets and the surface area, the following hypothesis may be in order: "The rate of absorption of any given amount of crystalline hormone depends on the number of pellets implanted at one time and not on the size or weight of the pellets, and the time that the

pellets continue to give off appreciable material depends on the size and weight of the pellets implanted.¹⁰ The manner of absorption is mainly a physical phenomenon depending on the surface area exposed to the dissolving action of tissue fluids. Influencing factors are the density of the pellet, the size of the particles (crystals) that comprise the pellet, and the site of implantation.⁸

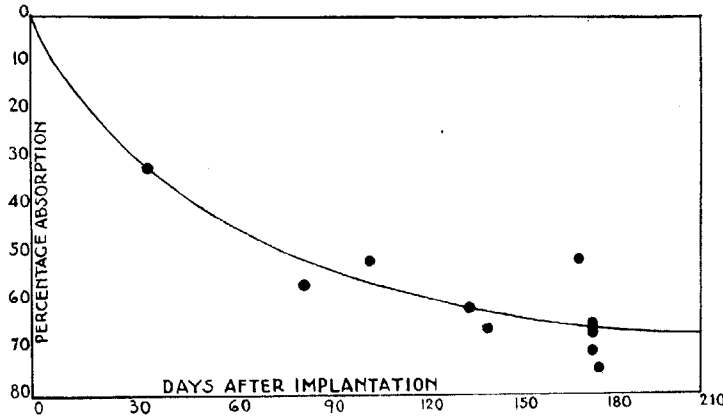


Fig. 5.—Percentage mean absorption curve for 100 mg. pellets of testosterone propionate. (From: Greenblatt, R. B., and Hair, L. Q.: *J. Clin. Endocrinol.* 2: 315, 1942.)

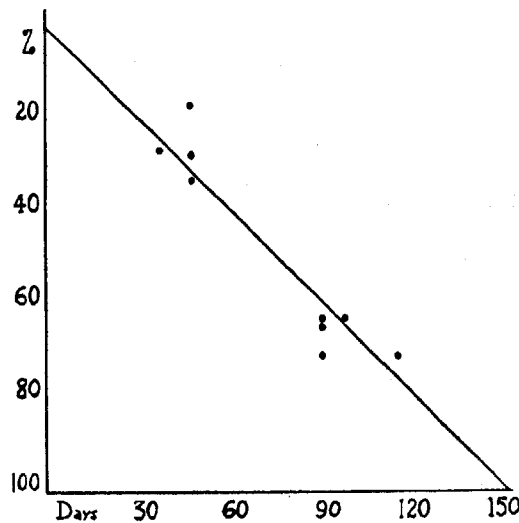


Fig. 6.—Percentage absorption of 50 mg. pellets of progesterone. (From: Greenblatt, R. B., and Hair, L. Q.: *J. Clin. Endocrinol.* 5: 38, 1945.)

When the percentage absorption is plotted against the number of days that the pellets remain in situ, the resultant curves are more or less smooth with the individual deviations of each weight group being only moderate in extent. The percentage of absorption during the first month is relatively rapid for all groups. The rate of absorption progressively decreases with each suc-

ceeding month, the curve tending to level after the hundredth day. The decrease in rate of absorption is inversely proportional to the surface of the pellet. Fig. 5 shows the percentage mean absorption curve for 100 mg. pellets of testosterone propionate.⁸ Fig. 6 shows the percentage absorption of 50 mg. pellets of progesterone.⁹

Indications for the Use of Pellets

Estradiol Pellets (25 mg. in weight).—

1. In patients with severe menopausal syndrome in whom prolonged injections of estrogens are necessary.
2. In young women with hypoplasia of uterus or breasts.
3. Dysmenorrhea associated with hypoplasia of the uterus.

Note: Estradiol pellets are contraindicated in patients with a history of cancer or with so-called precancerous lesions. It is preferable that estradiol pellets should not be used except in those patients without uteri.

Progesterone Pellets (50 mg. in weight).—

1. May be used along with estrogens in the treatment of menopausal patients.
2. In selected patients with nervous tension states.
3. Nymphomaniacal tendencies that prove distressing.
4. In treatment of habitual abortion.¹¹
5. In treatment of puberal breast hypertrophy.⁹

Note: Combined estradiol-progesterone pellet implantation should never be used in the menopausal patient with an intact uterus, as prolonged bleeding usually ensues.

Testosterone Pellets (75 mg. in weight).—

1. In certain patients with symptoms of menopausal syndrome in whom estrogen therapy has proved unsatisfactory or is contraindicated.
2. In combination with estradiol pellets in patients with uteri who have severe menopausal symptoms, in order to prevent the untoward bleeding induced by estrogens.¹²
3. The dysmenorrhic patient with possible endometriosis or small fibroids.
4. The patient with fibromyomata for whom surgery is not feasible.
5. The patient with nocturia of endocrine origin.¹³
6. The female who is not psychologically frigid and in whom increased libido is desirable.¹⁴
7. As a palliative measure in patients with advanced carcinoma of the breast.
8. In combination with desoxycorticosterone pellets for Addison's disease.

Note: Testosterone pellets should not be used in women who have a tendency toward amenorrhea or hirsutism.

Desoxycorticosterone Acetate Pellets (75 mg. in weight).—

1. Addison's disease.¹⁵
2. In panhypopituitarism, pellets of desoxycorticosterone acetate may be implanted along with testosterone.
3. In certain asthenic patients who have low blood pressure, low blood sugar, and marked fatigability, it appears that this form of medication proves helpful.

Note: Desoxycorticosterone is contraindicated in hypertension or heart disease.

Typical Case Reports

Climacteric.—

(1) *Estradiol Pellets*: D. E., a 56-year-old white woman, was seen in April, 1947. Hysterectomy had been performed in 1936. During the preceding seven years, the patient

had frequent hot flushes, cried easily, was unable to concentrate, and stated that her memory was poor. Her emotions were easily disturbed. She had received repeated courses of estrogen therapy, orally and parenterally, with only partial alleviation of symptoms. In April, 1947, two 25 mg. pellets of estradiol were implanted. Improvement was noted almost immediately. The hot flushes were practically eliminated. Her emotions stabilized, she was more receptive to visitors, and her attitude to life in general was greatly improved. Her symptoms have remained under control for a period of ten months.

(2) *Estradiol and Testosterone Pellets:* B. B., a 50-year-old white woman, was first seen Aug. 22, 1942, complaining of frequent, severe hot flushes, nocturia, nervousness, backache, headaches, and paresthesia. Menses had ceased three years previously. During the following five years the patient was treated with estrogens, progestogens, and androgens, given orally and parenterally, with unsatisfactory results. On October 6, 1947, the patient's complaints were particularly severe. At this time two 25 mg. pellets of estradiol, and one 75 mg. pellet of testosterone were implanted. Improvement was noted shortly. She experienced almost complete relief of all symptoms, and her complaints have been satisfactorily controlled during the six months' follow-up to date. No untoward bleeding occurred.

(3) *Estradiol, Progesterone, and Testosterone Pellets:* B. J., a white woman aged 41 years, was seen on Nov. 14, 1946. Her uterus, tubes, and ovaries had been surgically removed in 1939. The patient complained of fatigue, emotional instability with nervousness, and extreme depression, formication, and occasional hot flushes. She was treated with oral estrogens for several weeks, and showed some improvement. On Jan. 13, 1947, one 25 mg. pellet of estradiol, one 50 mg. pellet of progesterone, and one 75 mg. pellet of testosterone were implanted. She was seen the following month and stated that her symptoms were completely ameliorated. The symptoms remained under control for six months. On July 3, 1947, the patient returned, and reported that there was a decline in her well-being. One 25 mg. pellet of estradiol, and one 75 mg. pellet of testosterone were implanted. She remained in good health during the next six months, but noted somewhat less improvement than following the first series of pellets. She returned on Jan. 9, 1948, because some of her symptoms were becoming manifest, however slight. She feared a recurrence, and requested a repeat implantation. One 25 mg. pellet of estradiol, one 50 mg. pellet of progesterone, and one 75 mg. pellet of testosterone were again implanted. Her complaints were again quickly relieved, and she has remained in good health to date.

Habitual Abortion.—

Estradiol and Progesterone Pellets: J. W., a gravida v, para i, white woman aged 43 years of age, was seen June 5, 1946, with a history of three abortions following the birth of her first child in 1936. Each abortion occurred between the second and third months of gestation. She also had one abortion prior to the first child. At the time of her visit, the period was approximately one week overdue, the date of the last menstrual period being April 28. Examination suggested pregnancy, and the pregnancy test was reported positive. Two 25 mg. pellets of estradiol, and three 50 mg. pellets of progesterone were implanted. The patient was kept at bed rest until the seventh month of gestation. Thyroid and vitamin E were prescribed. During the fifth, sixth, and early part of the seventh months, 5 mg. of progesterone were given by injection twice weekly. At no time during the course of pregnancy was there any evidence of threatening abortion. The patient was delivered of a normal, 7¼ lb. female infant on Jan. 30, 1947.

Loss of Libido.—

Testosterone Pellets.—G. P., a white female of 31 years was seen on May 30, 1946. She had been married for 12 years, but had no children. She complained of nervousness, backache, severe headaches, insomnia, and swelling of feet and ankles. She had not menstruated during the preceding year, although previously the menses had been regular. Her libido was markedly diminished. Examination revealed an infantile uterus. Suction curettage was performed, and the endometrium was atrophic. The vaginal smear showed mostly basal cells. A diagnosis was made of precocious menopause, with marked reduction of libido. The patient was treated with stilbestrol, thyroid, and vitamin B for three weeks, with only slight improvement. On July 11, 1946, two 75 mg. pellets of testosterone were implanted.

She was seen again August 22, and stated that her condition was greatly improved. Headaches had ceased, she slept well, and her libido was definitely increased. Examination showed the clitoris to be slightly enlarged, and very sensitive. The patient returned March 11, 1947, and stated that symptoms had been adequately controlled for seven months, but recently her well-being and libido had lessened. Two 75 mg. pellets of testosterone were again implanted. There was immediate improvement, and her complaints were controlled for an additional period of five months. She was seen on Sept. 19, 1947, complaining of a recent decrease in libido. Two 75 mg. pellets of testosterone were implanted. Libido was restored, and remained at a high level for five months. She was last seen on Jan. 24, 1948, at which time one 25 mg. pellet of estradiol, and one 75 mg. pellet of testosterone were implanted in order to maintain her well-being and clinical improvement.

Endometriosis.—

Testosterone Pellets: E. S., a 24-year-old white woman, complained of dysmenorrhea for the duration of the menses so severe that her physician had to resort to some opiate for relief. Following the cessation of flow, pain in the left side persisted for one week afterward. Examination revealed a retroverted adherent uterus, with tenderness and some fullness of the left fornix. A diagnosis was made of endometriosis. In 1943, complete relief was afforded for a period of six months by injections of testosterone propionate, 25 mg. every fifth day. Two months after the injections were discontinued, the pain returned. Therapy was resumed, and continued for eight months with amelioration of her syndrome. In April, 1946, the patient complained of excruciating pain in the left side for one week following menstruation. She had noticed burning on urination when the pain was present. The patient stated that she was relieved of the dysmenorrhea. At this time urologic consultation was sought, and the urologist concurred in the diagnosis of endometriosis. It was felt that the pain was produced by an endometrioma causing pressure on the ureter. Three 75 mg. pellets of testosterone were implanted. The pain was relieved for six months, but recurred following the next menstrual period. Pelvic examination showed the uterus still retroverted, but slightly more moveable. There was tenderness in the left fornix; and some induration of the left uterosacral ligament. Three 75 mg. pellets of testosterone were again implanted. There was no pain following menstruation in December. The patient became pregnant, but aborted in February, 1947. Shortly thereafter, she became pregnant again, and was delivered on Nov. 29, 1947, of a normal male infant.

Addison's Disease.—

Desoxycorticosterone and Testosterone Pellets: R. C., a 31-year-old white nullipara, was first seen in September, 1946. Her complaints were extreme weakness, headaches, marked generalized pigmentation especially of face and upper extremities, and partial loss of head, axillary, and pubic hair. The diagnosis of Addison's disease was confirmed by laboratory tests. At this time three 75 mg. pellets of desoxycorticosterone were implanted. Aqueous adrenal cortical extract was prescribed in 1 c.c. doses twice weekly. Extra salt was added to the diet. During the following three months the patient improved rapidly. On Dec. 12, 1946, one 75 mg. pellet of desoxycorticosterone was implanted. Improvement continued, and in May, 1947, three 75 mg. pellets of desoxycorticosterone, and two 75 mg. pellets of testosterone were implanted. The patient continued to do well. She gained weight, did not fatigue easily, hair growth was restored, and pigmentation decreased somewhat. On Aug. 12, 1947, one 75 mg. pellet of desoxycorticosterone, and one 75 mg. pellet of testosterone were implanted. The patient was last seen on Feb. 4, 1948. At this time she stated that she had not taken any adrenal cortical extract or extra salt for the past four months, and that she felt extremely well.

Summary

The implantation of hormonal pellets has proved of value in the management of a great variety of endocrine and gynecic disorders. Pellet implantation is indicated in those conditions where prolonged hormonal therapy appears necessary. With the use of the Kearns Pellet Injector, pellet implantation is a simple office procedure. Some of the indications and contraindications

for pellet implantation are listed. A number of typical case reports are cited in which pellet implantation was of definite benefit to the patient. It appears that the pellet method of hormone administration has more nearly approached the endogenous rate of hormonal secretion. Furthermore, its use has made possible a clearer understanding of the physiologic properties of certain steroids.

Testosterone and desoxycorticosterone acetate pellets are now commercially available, and it is hoped that pellets of estradiol and progesterone will soon be made available for general use.

References

1. Deansley, R., and Parkes, A. S.: Proc. Roy. Soc., London, s.B. 124: 279, 1937.
2. Thorne, C. W., Howard, R. P., and Emerson, K., Jr.: Bull. Johns Hopkins Hosp. 64: 339, 1939.
3. Hartman, C. G.: Endocrinology 26: 449, 1940.
4. Looser, A. A.: Brit. M. J. 1: 497, 1940.
5. Greenblatt, R. B., and Wilcox, E. A.: South Surgeon 10: 339, 1941.
6. Greenblatt, R. B.: J. A. M. A. 121: 17, 1943.
7. Corner, G. W.: The Hormones in Human Reproduction, Princeton, N. J., 1942, Princeton University Press, p. 192.
8. Greenblatt, R. B., and Hair, L. Q.: J. Clin. Endocrinol. 2: 315, 1942.
9. Greenblatt, R. B., and Hair, L. Q.: J. Clin. Endocrinol. 5: 38, 1945.
10. Greenblatt, R. B.: Office Endocrinology, Springfield, Ill., 1947, Charles C. Thomas, p. 238.
11. Mishell, D. R.: AM. J. OBST. & GYNEC. 41: 687, 1941.
12. Greenblatt, R. B., and Suran, R. R.: J. Clin. Endocrinol. 8: 614, 1948. (Abstr.)
13. a. Greenblatt, R. B.: J. M. A. Georgia 31: 381, 1942.
b. Greenblatt, R. B.: J. Clin. Endocrinol. 2: 321, 1942.
c. Bickers, W.: Urol. & Cutan. Rev. 49: 397, 1945.
14. Greenblatt, R. B., Mortara, F., and Torpin, R.: AM. J. OBST. & GYNEC. 44: 630, 1942.
15. Kemper, C. F.: Ann. Int. Med. 22: 161, 1945.