

Circulation

JOURNAL OF THE AMERICAN HEART ASSOCIATION



Effect of Testosterone on Plaque Development and Androgen Receptor Expression in the Arterial Vessel Wall

Hartmut Hanke, Christina Lenz, Beate Hess, Klaus-Dieter Spindler and Wolfgang Weidemann

Circulation 2001;103:1382-1385

Circulation is published by the American Heart Association, 7272 Greenville Avenue, Dallas, TX 75214

Copyright © 2001 American Heart Association. All rights reserved. Print ISSN: 0009-7322. Online ISSN: 1524-4539

The online version of this article, along with updated information and services, is located on the World Wide Web at:

<http://circ.ahajournals.org/cgi/content/full/103/10/1382>

Subscriptions: Information about subscribing to *Circulation* is online at
<http://circ.ahajournals.org/subscriptions/>

Permissions: Permissions & Rights Desk, Lippincott Williams & Wilkins, 351 West Camden Street, Baltimore, MD 21202-2436. Phone 410-5280-4050. Fax: 410-528-8550. Email:
journalpermissions@lww.com

Reprints: Information about reprints can be found online at
<http://www.lww.com/static/html/reprints.html>

Effect of Testosterone on Plaque Development and Androgen Receptor Expression in the Arterial Vessel Wall

Hartmut Hanke, MD, FESC; Christina Lenz; Beate Hess, BSc;
Klaus-Dieter Spindler, PhD; Wolfgang Weidemann, PhD

Background—Recent studies have suggested that testosterone has a protective effect in the arterial vascular system. However, little is known about the molecular aspects of the mechanism(s) involved in these processes. The aim of the present study was to investigate the effect of testosterone on neointimal plaque development and on the expression of the vascular androgen receptor.

Methods and Results—Neointimal plaque formation was induced by endothelial denudation in the aortas of male New Zealand White rabbits. Aortic ring segments were cultured for 21 days after endothelial denudation. Testosterone was applied to the culture medium in different doses. Compared with the non-hormone-treated control group, a significant inhibition of neointimal plaque development (expressed as the intima/media ratio) was found at testosterone concentrations of 10 ng/mL ($P=0.037$) and 100 ng/mL ($P=0.012$; intima/media ratios: median of controls, 0.25; median of 10 ng/mL testosterone group, 0.15; median of 100 ng/mL testosterone group, 0.16). Associated with this inhibitory effect on plaque size was a 50% increase of the amount of androgen receptor mRNA in the arterial segments treated with testosterone.

Conclusion—The beneficial effects of testosterone on postinjury plaque development underlines, at least in males, the important role of androgens in the vascular system. As our data suggest, the vascular androgen receptor is probably involved in these processes. Further studies are required to characterize the androgen receptor-dependent pathways in the vascular system. (*Circulation*. 2001;103:1382-1385.)

Key Words: testosterone ■ receptors, androgen ■ atherosclerosis

The role of androgens in atherogenesis is controversial¹; however, in recent years, several authors have found a number of beneficial effects of testosterone, at least in men. Animal studies have documented an inhibitory effect on plaque development in the cholesterol-fed rabbit model,^{2,3} whereas in recent clinical investigations, acute hemodynamic effects of testosterone on coronary vasomotion and stress-test induced ischemia were observed.^{4,5}

Thus far, only limited information is available regarding the possible involvement of arterial androgen receptors in these processes. Thus, the aim of the present study was to investigate, in an experimental model, (1) the dose-dependent effects of testosterone on plaque development, (2) the expression of the androgen receptor in arteries, and (3) possible dose-dependent changes of androgen receptor expression induced by testosterone.

Methods

Organ Culture System

Twelve-week-old male New Zealand White rabbits were used for the present study. The rabbits received standard chow without cholesterol (Altromin Inc) and were housed individually (no female rabbits

were present). After sacrifice, the abdomen was opened under sterile conditions, and the connective tissue was removed from the aorta. A 3F-Fogarty catheter (Baxter Inc) was inserted below the iliac bifurcation, and endothelial denudation was performed once with the inflated catheter. The aorta was then completely excised and cut into ≈ 30 rings that were ≈ 5 mm in length; the segments were then randomized into different study and control groups. A total of 80 aortic segments from 3 rabbits were used.

The aortic rings from the different study groups were kept separate in 6-well plates for 21 days at 37°C in phenol red-free Dulbecco's modified Eagle medium with Ham's F12 (Gibco) containing 4.5 g/L D-glucose, 15% fetal calf serum (Bio-Whittaker), and 5 mL/L penicillin streptomycin (Gibco). The medium for all groups contained 1% isopropanol and 1% dimethyl sulfoxide and was renewed 3 times a week, which included new testosterone application in different concentrations. Four different concentrations of testosterone (Sigma) were present for the 21 days after endothelial denudation (16 aortic segments in each group). One group of 16 aortic segments without hormone application served as controls.

Histological Examination

After 21 days under culture conditions, half of the aortic segments from each group were immersion-fixed in 4% paraformaldehyde solution, embedded in paraffin, and cut in 4- μ m slices. After elastica van-Gieson's staining, the neointimal and medial areas in the histological cross-sections were measured morphometrically.⁶ The

Received November 20, 2000; revision received January 12, 2001; accepted January 19, 2001.

From the Department of Internal Medicine/Cardiology and the Department of General Zoology and Endocrinology, University of Ulm, Germany. Correspondence to Hartmut Hanke, Department of Internal Medicine/Cardiology, Robert-Koch-Str 8, 89081 Ulm, Germany. E-mail hartmut.hanke@medizin.uni-ulm.de

© 2001 American Heart Association, Inc.

Circulation is available at <http://www.circulationaha.org>

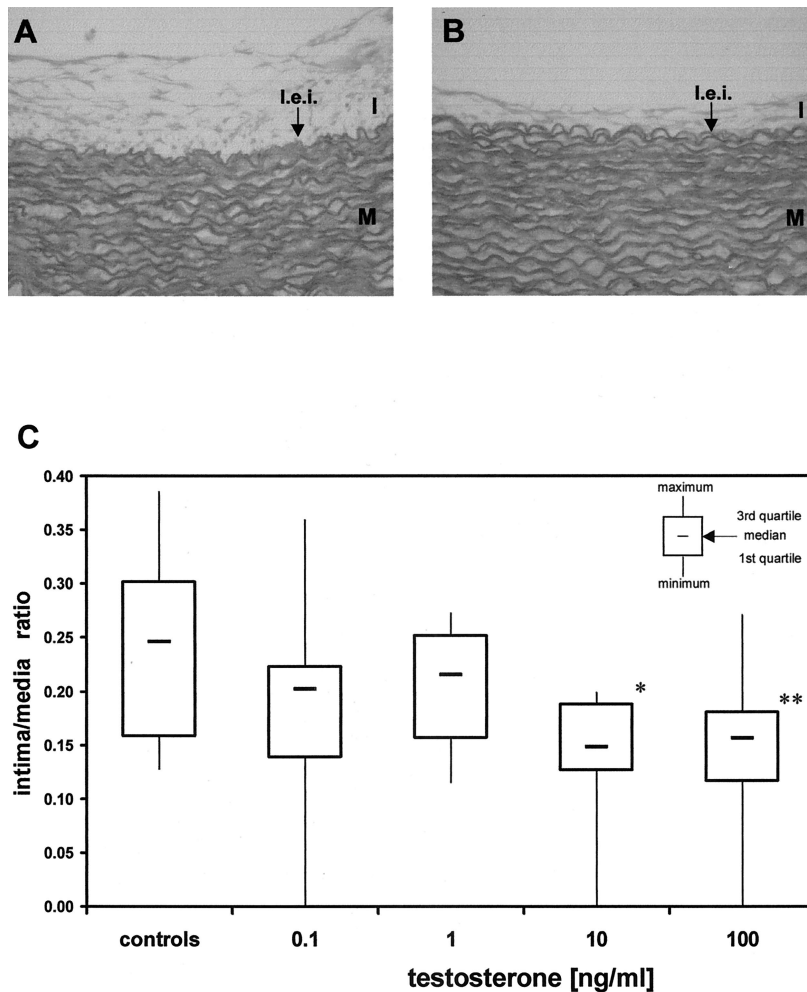


Figure 1. A, Histological cross-section of rabbit aortic segment after balloon denudation without hormone treatment (control group) showing neointimal plaque formation at site of injury. B, Histological cross-section of aortic segment treated with testosterone at a concentration of 10 ng/mL. As a result of inhibitory effect of testosterone, plaque development was reduced (Elastica van Gieson's staining; original magnification, $\times 50$). I indicates neointima; M, media; and I.e.i., lamina elastica interna. C, Bar graph showing intima/media ratio after morphometric analysis of neointimal plaque size and medial area. Significant reduction of plaque development was found with 10 ng/mL and 100 ng/mL testosterone. * $P=0.037$; ** $P=0.012$.

ratio of intima to media was then calculated and used for statistical evaluation.

Reverse Transcription–Polymerase Chain Reaction Analysis

For semiquantitative reverse transcription–polymerase chain reaction (RT-PCR) analysis, total RNA from the remaining segments of each group was extracted using Trizol reagent (GibcoBRL). The total RNA was reverse-transcribed using oligo(dT) primer and reverse transcriptase from GibcoBRL. PCR was performed using Taq DNA-polymerase (Roche). Primers for androgen receptor, selected from the rabbit androgen receptor cDNA sequence,⁷ were forward primer 5'-TGAGGCACCTCTCTCAAGA-3' and reverse primer 5'-AAGGCACTGCAGAGAAGTA-3', which yielded a 495-bp PCR product. Reactions were performed for 32 cycles of denaturation (60 s at 94°C), annealing (60 s at 60°C), and extension (120 s at 72°C). The amplified products were separated on agarose gels and quantified densitometrically (Multi-Analyst.1.1, Bio-Rad Laboratory). Values obtained were standardized by using the level of glyceraldehyde-3-phosphate dehydrogenase (GAPDH) mRNA, as determined by PCR. Primers, selected from the rabbit GAPDH cDNA sequence,⁸ were forward primer 5'-GATGGTGAAGGTCG-GAGTGAA-3' and reverse primer 5'-GGTGAAGACGCCAGTGG-ATT-3', which yielded a 304-bp PCR product. Reactions were performed for 26 cycles of denaturation (60 s at 94°C), annealing (60 s at 60°C), and extension (120 s at 72°C).

A total of 7 independent PCR assays of the testosterone-treated aortic segments were performed.

Statistical Analysis

The range of data, the median, and the first and third quartiles are shown for the morphometric data (intima/media ratio). Multiple ANOVA with 5 repeated measures was performed to determine the significance of differences in the extent of neointimal plaque development and androgen receptor expression (adjusted for GAPDH expression by using the individual densitometric data). For presentation in figures, the GAPDH-adjusted expression of the androgen receptor was calculated as percent changes from the control group in mean \pm SEM. Differences were considered statistically significant when $P < 0.05$.

Results

Morphological Data

Endothelial denudation was associated with considerable plaque development in the control segments (median of the intima/media-ratio: 0.25; Figure 1A). With testosterone, significant reductions of neointimal plaque size were found (Figures 1B and 1C) at testosterone concentrations of 10 and 100 ng/mL (medians of the intima/media-ratio: 0.15 and 0.16, respectively).

Androgen Receptor Expression

As shown in Figure 2, we found a significant increase of the amount of androgen receptor mRNA in the testosterone-treated segments at concentrations of 1 ng/mL and 10 ng/mL

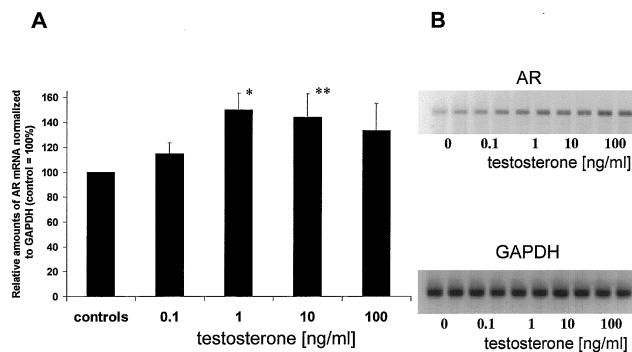


Figure 2. A, Bar graph showing a dose-dependent effect of testosterone on androgen receptor (AR) expression analyzed by semiquantitative RT-PCR. Compared with controls, a nearly 50% increase in amount of androgen receptor mRNA was found at concentrations of 1 and 10 ng/mL testosterone (* $P=0.032$; ** $P=0.035$). B, Representative examples of androgen receptor and GAPDH RT-PCR amplifications. Amount of androgen receptor mRNA increased with testosterone.

testosterone (standardized on GAPDH expression). In higher concentrations of testosterone, no further increase of the amount of androgen receptor mRNA occurred.

Discussion

Using data from previous animal studies,^{2,3} it was postulated that genomic actions are involved in mediating the protective effects of testosterone in the process of atherosclerosis. We hypothesized that vascular androgen receptors might play an important role in signaling the testosterone effects on the level of the arterial vessel wall. Therefore, our study was designed to investigate the effect(s) of testosterone on plaque development and arterial androgen receptor mRNA expression.

The present work is the first showing an upregulation of the expression of arterial androgen receptor mRNA with testosterone; this upregulation was also associated with a significant reduction of neointimal plaque development. It is of interest that the testosterone concentrations necessary for plaque inhibition are in the range of physiological concentrations.³

Because our morphological findings conform with previous in vivo studies in the rabbit model,^{2,3} the organ culture system might be a useful and appropriate model to investigate direct steroid hormone effects at the level of the arterial vessel wall without the interference of humoral factors. An additional advantage of the organ culture model is the fact that complete aortic segments were used, which allows for conventional histology and detailed molecular analysis. Because the standard chow the rabbits ate before starting the experiment contains soy protein, additional influences of phytoestrogens might be possible. However, at least during the 21 days of organ culture conditions, such effects can be excluded. The organ culture model is limited by the lack of an additional influence of cholesterol during plaque development. The induced neointimal lesion in that model is therefore mostly the result of the activation and proliferation of vascular smooth muscle cells, which represents only one (albeit essential) part in the process of early atherogenesis.⁹

Considering the effects of testosterone on vasomotion, it might be speculated that different pathways of action exist. Nongenomic effects might be responsible for the observed vasodilatation induced by the intracoronary administration of testosterone in men with coronary artery disease⁴ and in previous in vitro studies.¹⁰ In previous experimental animal studies,^{2,6} a sex-specific difference in the action of testosterone and estrogen was found. Testosterone in male rabbits had an inhibitory effect on plaque development, but in female rabbits, an atheroprotective action of testosterone was found.²

These findings indirectly provide support for the hypothesis that arterial sex hormone receptors are probably involved as one part of the genomic actions of sex steroids on the level of the arterial vessel wall.¹¹

Androgen and estrogen receptors are present in vascular smooth muscle cells,^{11,12} human macrophages, human megakaryocytes, and platelets.^{13,14} Interestingly, McCrohon et al¹⁵ found sex-specific differences in androgen receptor expression in human macrophages. Furthermore, in human megakaryocytes, the androgen receptor was upregulated by testosterone at a concentration of 10 nmol/L, whereas downregulation occurred at a concentration of 100 nmol/L.¹⁴ Considering the observations in other target tissues and androgen receptor-containing cell lines,¹⁶ these findings underline the complexity of androgen receptor regulation by androgens, which involves several levels, including transcriptional, translational, and post-translational mechanisms.

In conclusion, our present data suggest the involvement of the arterial androgen receptor in mediating the beneficial vascular effects of testosterone. However, further work is required to characterize the intracellular signal transduction pathways of testosterone action, including the possible aromatization of testosterone to estradiol, and the role of involved vascular sex hormone receptors.

Acknowledgments

Beate Hess was supported by a grant from the Ernst und Berta Grimmke-Stiftung, Düsseldorf, Germany. The authors thank Dr Martin Höher for his help in statistical analysis and Tarek El-Bahay for his advice and assistance throughout the study.

References

- Alexandersen P, Haarbo J, Christiansen C. The relationship of natural androgens to coronary heart disease in males: a review. *Atherosclerosis*. 1996;125:1–13.
- Bruck B, Brehme U, Gugel N, et al. Gender-specific differences in the effects of testosterone and estrogen on the development of atherosclerosis in rabbits. *Arterioscler Thromb Vasc Biol*. 1997;17:2192–2199.
- Alexandersen P, Haarbo J, Byrjalsen et al. Natural androgens inhibit male atherosclerosis: a study in castrated, cholesterol-fed rabbits. *Circ Res*. 1999;84:813–819.
- Webb CM, McNeill JG, Hayward CS, et al. Effects of testosterone on coronary vasomotor regulation in men with coronary heart disease. *Circulation*. 1999;100:1690–1696.
- Rosano GMC, Leonardo F, Pagnotta P, et al. Acute anti-ischemic effect of testosterone in men with coronary artery disease. *Circulation*. 1999;99:1666–1670.
- Hanke H, Hanke S, Finking G, et al. Different effects of estrogen and progesterone on experimental atherosclerosis in female versus male rabbits. *Circulation*. 1996;94:175–181.
- Krongrad A, Wilson JD, McPhaul MJ. Cloning and partial sequence of the rabbit androgen receptor: expression in fetal urogenital tissues. *J Androl*. 1995;16:209–212.

8. Applequist SE, Keyna U, Calvin MR, et al. Sequence of the rabbit glyceraldehyde-3-phosphate dehydrogenase-encoding cDNA. *Gene*. 1995;163:325–326.
9. Ross R, Glomset GA. Atherosclerosis and the arterial smooth muscle: proliferation of smooth muscle cell is a key event in the genesis of the lesions of atherosclerosis. *Science*. 1973;180:1332–1339.
10. Yue P, Chatterjee K, Beale C, et al. Testosterone relaxes rabbit coronary arteries and aorta. *Circulation*. 1995;91:1154–1160.
11. Mendelsohn ME, Karas RH. The protective effects of estrogen on the cardiovascular system. *N Engl J Med*. 1999;340:1801–1811.
12. Fujimoto R, Morimoto I, Morita E, et al. Androgen receptors, 5 alpha-reductase activity and androgen-dependent proliferation of vascular smooth muscle cells. *J Steroid Biochem Mol Biol*. 1994;50:169–174.
13. Cutolo M, Accardo S, Villagio B, et al. Androgen and estrogen receptors are present in primary cultures of human synovial macrophages. *J Endocrinol Metab*. 1996;81:820–827.
14. Khetawat G, Faraday N, Nealen ML, et al. Human megakaryocytes and platelets contain the estrogen receptor β and androgen receptor (AR): testosterone regulates AR expression. *Blood*. 2000;95:2289–2296.
15. McCrohon JA, Death AK, Nakhla S, et al. Androgen receptor expression is greater in macrophages from male than from female donors: a sex difference with implications for atherogenesis. *Circulation*. 2000;101:224–226.
16. Quigley CA, de Bellis A, Marschke KB, et al. Androgen receptor defects: historical, clinical, and molecular perspectives. *Endocr Rev*. 1995;16:271–319.