

CLINICAL EXPERIMENTS WITH ANDROGENS

IV. A METHOD OF IMPLANTATION OF CRYSTALLINE TESTOSTERONE

SAMUEL A. VEST, M.D.

CHARLOTTESVILLE, VA.

AND

JOHN E. HOWARD, M.D.

BALTIMORE

From experimental observations it is well known that androgenic substances are chemically changed and excreted after entering the circulation. The effectiveness of any androgenic preparation depends on many factors. One of the most important, besides the frequency of administration and the dosage, is the method of administration. The use of various solvents, the addition of fatty acids to the androgenic solutions, esterification of the substances and many other variations have been studied in an attempt to increase the efficiency of administration of androgenic substances. The fact that pure crystalline testosterone is readily absorbed by the body fluids undoubtedly leads to waste when excess material is given. In order to overcome this difficulty and to decrease the rate of absorption, testosterone has usually been injected in an oily solution as the propionate. Injection of testosterone propionate has proved far more effective than the equivalent amounts of free testosterone. The intensity and duration of the action of testosterone has been thus enhanced, and treatment of hypogonadism in human beings has been satisfactorily carried out with injections at intervals of from three to four days.¹ From the results of animal experiments it would appear that when large amounts of testosterone propionate are injected at such intervals an appreciable proportion of the substance is wasted. Testosterone has also been used clinically in the form of innunctions and by oral administration. It is not entirely satisfactory in the form of innunctions and when given by mouth enormous amounts are necessary to elicit clinical response. A method of administration which would tend to simulate the secretion of this hormone by the testis has been sought. If androgenic substance can be administered so that the amount absorbed daily is not in excess of the physiologic requirements, waste will be eliminated and expense can be kept to a minimum. Before the prevalent intramuscular injection of the testosterone propionate in an oily solution is supplanted, a new method must prove to be more convenient, more efficient, less expensive and devoid of harmful consequences.

The first use of pure androgens and estrogens by subcutaneous implantation of crystals or pellets was reported by Deanesly and Parkes² in 1937 and 1938. Their work indicated that tablets of compressed crys-

tals implanted subcutaneously produced stronger and longer effects of stimulation than similar doses given by injection. Schoeller and Gehrke³ later showed the superior effect of implanted testosterone and testosterone propionate tablets in fowls. Having knowledge at the time of the work that Deanesly was carrying out in experimental animals, we first implanted pellets of crystalline testosterone subcutaneously into a patient with hypogonadism in the fall of 1937, but these pellets were too small to produce any significant clinical results. Three recent reports⁴ have referred to the




Fig. 1.—The instruments used to make pellets of various sizes. A, the press; B, the die with three sizes of pellets; C, the punches; D, the assembled press with a punch in place; E, the heavy metal mallet.

implantation of small pellets of testosterone in human beings with questionable results. In the fall of 1938, soon after Thorn⁵ began his work with the implanta-

From the James Buchanan Brady Urological Institute and the Department of Medicine of the Johns Hopkins University and Hospital.

This work has been aided by a grant from the Ciba Pharmaceutical Products, Inc., which also supplied the testosterone, and by a fellowship from the Lator Foundation.

This method was presented in brief in a discussion before the Section on Urology at the Ninetieth Annual Session of the American Medical Association, St. Louis, May 18, 1939.

1. Vest, S. A., and Howard, J. E.: Clinical Experiments with the Use of Male Sex Hormones: Use of Testosterone Propionate in Hypogonadism, *J. Urol.* **40**: 154-183 (July) 1938. Howard and Vest.⁶

2. Deanesly, Ruth, and Parkes, A. S.: Factors Influencing Effectiveness of Administered Hormones, *Proc. Roy. Soc., London*, s. B **124**: 279-298 (Dec. 7) 1937; Biological Properties of Some New Derivatives of Testosterone, *Biochem. J.* **31**: 1161-1164 (July) 1937; Further Experiments on Administration of Hormones by Subcutaneous Implantation of Tablets, *Lancet* **2**: 606-608 (Sept. 10) 1938. Deanesly, Ruth: Use of Castrated Mice for Testing Androgenic Substances, *Quart. J. Pharm. & Pharmacol.* **11**: 79-83 (Jan.-March) 1938.

3. Schoeller, W., and Gehrke, M.: Tierphysiologische Versuche über die Wirkung männlicher Keimdrüsenhormone: Versuche an Kapaunen, *Klin. Wchnschr.* **17**: 694-699 (May 14) 1938.

4. Lippross, O.: Ergebnisse der Behandlung männlicher Keimdrüsenhormonen, *München. med. Wchnschr.* **85**: 1668-1672 (Oct. 28) 1938. Foss, G. L.: Clinical Administration of Androgens: Comparison of Various Methods, *Lancet* **1**: 502-504 (March 4) 1939. Hamilton, J. B., and Dorfman, R. I.: Influence of the Vehicle upon the Length and Strength of the Action of Male Hormone Substance Testosterone Propionate, *Endocrinology* **24**: 711-719 (May) 1939.

5. Thorn, G. W.; Engel, L. L., and Eisenberg, Harry: Treatment of Adrenal Insufficiency by Means of Subcutaneous Implants of Pellets of Desoxy-Corticosterone Acetate (A Synthetic Adrenal Cortical Hormone), *Bull. Johns Hopkins Hosp.* **64**: 155 (March) 1939.

tion of moderate sized pellets of desoxycorticosterone acetate, we began to make and implant pure testosterone in large pellets weighing up to 800 mg. We have now implanted these pellets into a series of thirteen patients with hypogonadism.⁶ We have implanted pellets subcutaneously or intramuscularly in the leg, arm, back




Fig. 2.—A, the "injector" instrument with fenestra closed; A', the mechanism to open and close fenestra at will; B, three sizes of pellets; C, instrument with fenestra opened by rotating handle (note the bladelikey point); D, end of injector showing obturator extruding a pellet; E, same as D but with two pellets being extruded.

and scrotum. The pellets have been removed later and reweighed in order to calculate the average amount that has been absorbed daily. The actual curve of absorption probably shows a gradual decrease as the size of the pellet becomes smaller. Tissues surrounding the pellets, which are foreign bodies, have been removed and studied pathologically. Assays of the urinary androgens and estrogens have been made before and after implantation. A systematic study of various aspects of pellet implantation with both crystalline testosterone and some of its esters is now being completed and an evaluation of the clinical results will be discussed in a forthcoming report.⁷ A study of the effects of testosterone and its esters in the monkey, comparing the method of injection with the implantation of pellets, is also in progress.⁸

Our purpose in this report is to present a new technic for the subcutaneous implantation of solids such as pellets of pure crystalline androgenic substance by the use of an "injector" instrument.⁹

If the slow absorption of subcutaneous androgenic substance in pellet form was to be more efficient per unit weight of material utilized, this advantage would be offset somewhat by the impracticability of the necessary incision for implantation. To obviate an operating room procedure, the following method was devised. Figure 1 A, B and C shows the press, die and punches used to make pellets of three different sizes. The pellets are shown in their corresponding slots. Figure 1 D

shows the assembled press with a punch in place. Figure 1 E shows the heavy metal hammer used to pound the previously sterilized, powdered testosterone into a very hard and compact pellet. These implements can be boiled and the pellets are made under sterile technic. It has been impossible to make pellets of uniform size and weight with such an apparatus, but for practical purposes it has served for our study. Many factors probably affect the absorption rate, the foremost of which are the surface area and the density of the pellet. Other possible factors are the vascularity of the site of implantation, the extent of the reaction to the foreign body and the degree of hormone deficiency. For absolute comparative values regarding absorption and clinical effect in a series of cases it would have been ideal to implant pellets of identical size and weight; but this was not possible.

Figure 2 A shows one of several instruments which we have devised on the principle of the syringe in order that solid pellets might be injected subcutaneously or intramuscularly in the office instead of in an oper-




Fig. 3.—Method of depositing pellet by means of a new "injector" instrument. A, instrument entering skin of leg through a wheal of local anesthetic; B, end of instrument below fascia lata with obturator being pushed forward to extrude and deposit pellet (the fenestra has been opened by rotating window); C, skin clip to close puncture wound.

ating room. It shows the instrument with the fenestra closed and the obturator slightly withdrawn. A scalpel-like point serves to pierce the skin, leaving a clean linear opening. Figure 2 B shows pellets of different caliber for which three sizes of instruments can be used, depending on the amount of material one desires to inject. The maximum amount injected with such

6. Howard, J. E., and Vest, S. A.: Clinical Experiments with the Use of Male Sex Hormones, *Am. J. M. Sc.*, to be published.

7. Howard, J. E., and Vest, S. A., to be published.

8. Vest, S. A.; Drew, Edwin, and Howard, J. E., to be published.

9. This instrument was developed with the assistance of Mr. Frederick C. Wappler, of the American Cystoscope Makers, Inc.

an instrument to date is two pellets of more than 400 mg. each at one time. Figure 2C shows the instrument with the fenestra open and the obturator withdrawn. Figure 2D shows the end of the "injector" or "implanter" with the fenestra open through which the obturator is extruding a pellet. Figure 2E shows how

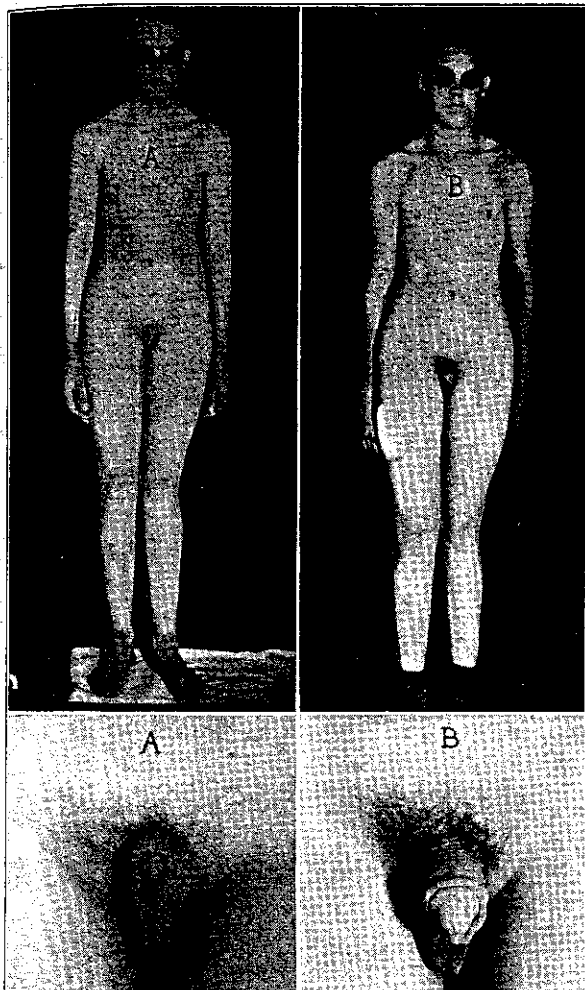


Fig. 4 (case 1).—Appearance of patient, aged 21, with hypogonadism before and after implantation of pellets of crystalline testosterone in muscle of back. A, full view and genitalia before implantation; B, same ninety days later.

two pellets can be injected, one following the other. The obturator can be entirely withdrawn and the pellets inserted into the proximal end of the barrel as desired instead of through the open fenestra. The fenestra can be opened and closed at will by means of the rotary barrel mechanism controlled at the handle.

The instrument is used in the following manner, as shown in figure 3. A wheal is made in the skin of the thigh with a solution of nupercaine. The instrument with the pellets of testosterone inside and the fenestra closed is pushed painlessly through the skin and, if desired, beneath the fascia lata (fig. 3A). In figure 3B the fenestra has been opened and the obturator is being pushed forward to extrude the pellets in the muscle of the thigh. The fenestra is then closed and the instrument is withdrawn, leaving the pellet in place as shown in fig. 3C. A silver clip has been used to close the puncture wound. A clip is not always necessary

because the margins of the skin of the 6 to 8 mm. puncture wound usually approximate themselves.

The following two cases are reported as examples of the clinical activity of testosterone when it is implanted into man in the form of pure crystalline pellets of large size:

CASE 1.—History.—W. A., a white youth aged 21, admitted to the James Buchanan Brady Urological Institute March 21, 1939, complained of having "never matured sexually." His two brothers developed normally. The usual changes of puberty, with the exception of the appearance of a few pubic hairs at the age of 15 to 16, did not occur in the patient. He stopped school in the eleventh grade because of his underdevelopment. His psychologic content was definitely male. Erections had occurred frequently in the mornings since the age of 17, and he masturbated several times a year but without ejaculation.

Examination.—Figure 4A shows the typical eunuchoid appearance. The patient was 5 feet 10½ inches (149 cm.) tall and weighed 142¾ pounds (64.8 Kg.). Roentgenograms showed a normal skull and sella, but there was retardation in the epiphysial closure of the bones. There was more than 25 but less than 50 rat units of follicle stimulating factor per liter of

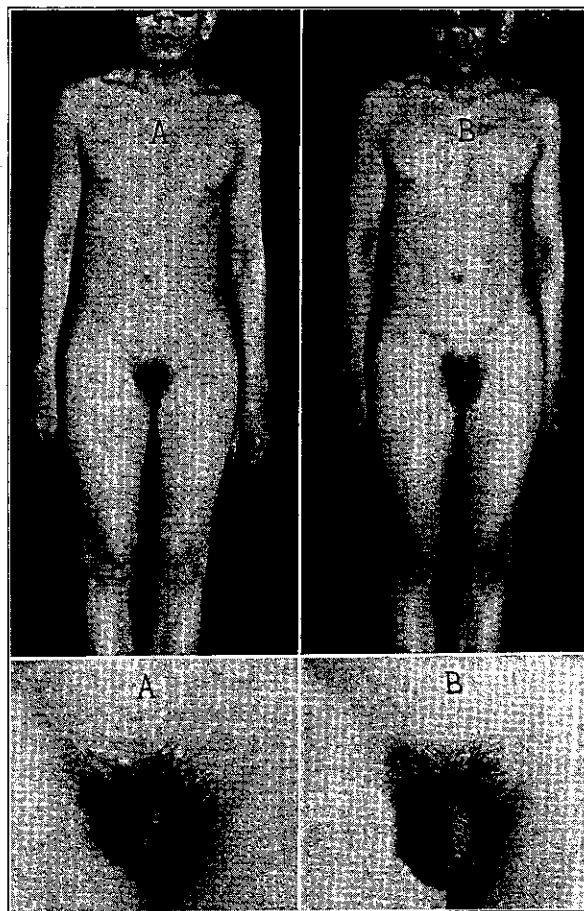


Fig. 5 (case 2).—Appearance of patient, aged 34, with hypogonadism before and after implantation of large pellet of testosterone weighing 750 mg. into scrotum. In some respects this could be termed a "synthetic testicle." A, full view and genitalia before implantation; B, same two and one-half months later. Slower absorption of large pellet in scrotum was taking place as compared to case 1.

urine. No hair was present on the face, extremities, abdomen or chest. The breasts were normal. The voice was high pitched. The penis was infantile (fig. 4A) and only 5 cm. long on complete extension. The testicles were about 4 to 5 mm. in diameter and were situated in the scrotum. The outlines of the prostate and seminal vesicles were impalpable. No secretion was expressed by massage of the prostatic region.

Treatment.—March 25 three pellets of crystalline testosterone weighing 277, 219 and 175 mg. were implanted in the right lumbar muscles. (In this case we used three relatively small pellets instead of one or two large ones because we wished to study the absorption rate of pellets of this size compared with the larger ones.)

Result.—The second day after implantation the patient began to notice an increased frequency of erections and he masturbated eight times in the subsequent three months. Ejaculation occurred for the first time in his life. The nipples soon became tender with the appearance of small lumps underneath, more marked on the left. At the end of the first month the voice began to

have found in other patients who received a single large pellet. The patient is now continuing to develop with a single pellet weighing 778 mg.

CASE 2.—History.—J. R., a man aged 34, entered the James Buchanan Brady Urological Institute April 1, 1939. His brothers were normally developed. At the age of 15 the patient had his present degree of pubescence. Since then he had had an occasional erection, with rare masturbation without ejaculation.

Examination.—The patient presented a eunuchoid appearance. Figure 5 A shows the patient before treatment. He was 5 feet 5 3/4 inches (167 cm.) tall. A roentgenogram showed delayed union of the epiphyses with the skeletal age of a youth 18 years old. There was present 25 rat units of follicle stimulating factor per liter. The genitalia were undeveloped (fig. 5 A). The penis was 4.5 cm. long on complete extension. The testes were 1 cm. long and were situated in the upper part of the scrotum. Considerable pubic, rectal and perineal hair was present. No hair was present on the chin, body or extremities. A tiny amount of prostatic tissue could be felt around the urethra. The seminal vesicles were indefinite. No secretion could be expressed by massage.

Treatment.—April 10 a pellet of pure testosterone weighing 750 mg. was implanted into the scrotum. The scrotum was selected because of its superficial position where the pellet could easily be palpated from time to time. It is possible that absorption from the scrotum is slower and not as satisfactory as from muscle or subcutaneous tissue.

Result.—Figure 5 B shows the patient's appearance two and one-half months after implantation, at which time it seemed by palpation that only about one third of the pellet had been absorbed. During this time he complained of erections practically all night and frequently during the day. The testes descended to the bottom of the scrotum so that the left came to lie just adjacent to the pellet. The voice became deeper. He gained 4 pounds (1,814 Gm.) the first two weeks and 3 pounds (1,307 Gm.) the following two weeks. He began to masturbate three or four times a week, with ejaculation. Slight tenderness appeared in both breasts, especially the left. Hair began to grow on the lower legs and the upper lip. In two and one-half months (fig. 5 B) the penis had increased in size and was now 6.3 cm. in complete extension. The prostate had developed to about two thirds normal size. It was normal in contour, shape and consistency. Several drops of secretion could be expressed which were normal in appearance and normal microscopically. The seminal vesicles were easily palpable and almost normal in size.

The clinical results, though just beginning in these patients, is indicative of the activity of crystalline testosterone when implanted subcutaneously in the form of pellets. The method may prove to have important clinical applications, but more extensive work is necessary to establish this with certainty.

It has been of interest to study the type of tissue reactions which occur around pellets of testosterone. Figure 6 A and B shows photomicrographs of the tissue encapsulating pellets four months after implantation. In figure 6 A the cavity in which the pellet was situated is visible. Surrounding this cavity is granulation tissue containing many foreign-body giant cells, an occasional leukocyte and some round cells, all lying in a fibroblastic matrix. In 6 B (another case) there is less reaction to the foreign body, with only a rare giant cell. Much fibrous scar tissue has developed, some of which is hyaline. A dense collection and some diffuse round cells are seen. There is no evidence of unusual cellular reaction, metaplasia or carcinogenic activity.

It is possible that such an instrument as we have developed and presented here might be applicable to injection of other solid medicinal materials.

University Hospital, Charlottesville, Va.—24 East Eager Street, Baltimore.

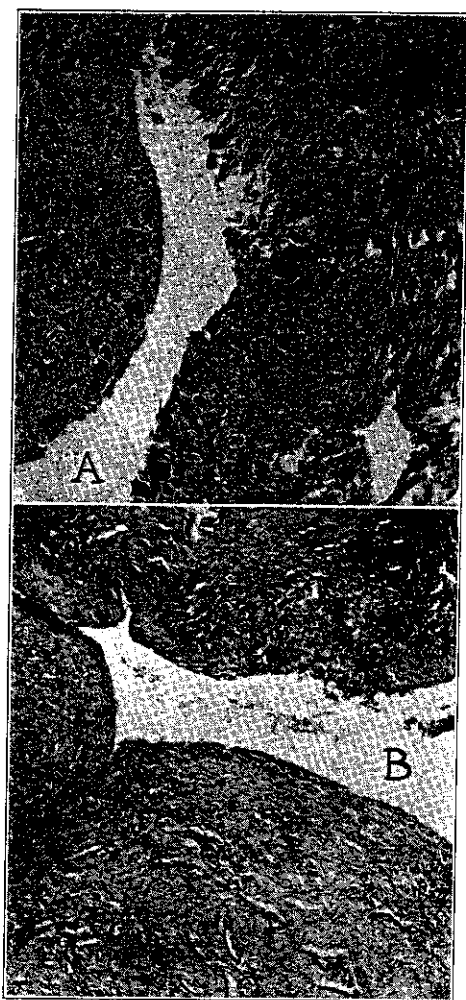


Fig. 6.—Sections of tissue showing reaction around cavities where pellets had been placed for three months in the subcutaneous tissue of arms of two patients. A, many giant cells with some round cells and leukocytes; B, fibrous tissue, some of which is hyaline, and a dense collection of round cells.

crack and assume a lower pitch. At the end of three months (June 23) a distinct increase of pubic hair had occurred, together with the appearance of profuse, thin, short hairs on the lower legs. The scrotum became larger and darker. The prostate was then three fourths of the normal adult size and of normal consistency and contour. The seminal vesicles were, however, barely palpable. Normal prostatic secretion was expressed. The penis increased in diameter and when completely extended measured 8.5 cm. Figure 4 B shows the patient's appearance June 23, ninety days after the pellet implantation. During this period he absorbed the three pellets completely, an average of at least 6.9 mg. a day. Pellets of this size absorb rapidly; his absorption rate was approximately twice that of what we